

H. Trimarchi
G. Casas
R. Jordan
J. Martínez
J. Schropp
E.A.R. Freixas
E. Efrón

Cytomegalovirus maculopapular eruption in a kidney transplant patient

Key words:

cytomegalovirus; kidney transplantation; skin; ganciclovir; immunosuppression

Abstract: Cytomegalovirus (CMV) is the most important viral agent in kidney transplantation. Clinical manifestations of CMV disease in transplantation include hepatitis, pneumonitis, pancreatitis, kidney allograft dysfunction, colitis, and meningoencephalitis. However, skin involvement is rare. We describe a severely compromised cadaveric-kidney transplant recipient who developed renal failure, colonic ulcers, and a maculopapular rash accompanied by fever and malaise 4 months after transplantation. Only the skin biopsy was diagnostic and consistent with CMV disease. Intravenous ganciclovir administration resulted in clinical improvement of CMV-induced skin lesions; kidney function normalized and the patient became asymptomatic after 14 days of ganciclovir therapy. Nephrologists should consider the diagnosis of CMV disease in the febrile immunosuppressed patient with skin involvement. Skin biopsy must be considered as a useful and safe procedure in patients with a rash to obtain a prompt diagnosis and efficiently treat this immunocompromised population.

Cytomegalovirus (CMV) infection occurs mainly after the first month of solid-organ transplantation, with an estimated incidence of 30–50%, depending on the serologic status of both donor and recipient and the type of transplanted organ. Exposure to the virus increases with age in the general population, and virus is present in more than 65% of donors and recipients at the time of transplantation. Moreover, the concurrent administration of immunosuppressants further raises the risk of clinically relevant CMV disease (1–3). It has been estimated that in renal transplant recipients 20% of graft failures, 30% of febrile episodes, 35% of leukopenic episodes, and 25% of deaths are caused by CMV (4). As in this case report, seropositive recipients of CMV-positive kidneys are at risk for both reactivation of latent virus and superinfection with a new viral strain, despite adequate viral prophylaxis.

CMV infection is usually defined as the documentation of viral replication, and can be symptomatic or asymptomatic. CMV overt infection (called CMV disease) can present as a mild disease with

Authors' affiliations:

Hernán Trimarchi¹,
Gabriel Casas²,
Rosana Jordan³,
Jorge Martínez³,
Juan Schropp¹,
Emilio AR Freixas¹,
Ernesto Efrón³

¹Department of Nephrology,
Hospital Británico de Buenos
Aires, Argentina,

²Department of Pathology,
Hospital Británico de Buenos
Aires, Argentina,

³Department of Infectious
Diseases, Hospital Británico
de Buenos Aires, Argentina

Correspondence to:

Hernán Trimarchi, MD
Hospital Británico de
Buenos Aires
Perdriel 74 (1280)
Buenos Aires
Argentina
Tel: +5411 4309 6400
Fax: +5411 4304 3393
e-mail:
htrimarchi@hotmail.com

Received 7 April, accepted for publication 29 August 2000

Copyright © Munksgaard 2001
Transplant Infectious Disease . ISSN 1398-2273

Transpl Infect Dis 2001; 3: 47–50
Printed in Denmark . All rights reserved

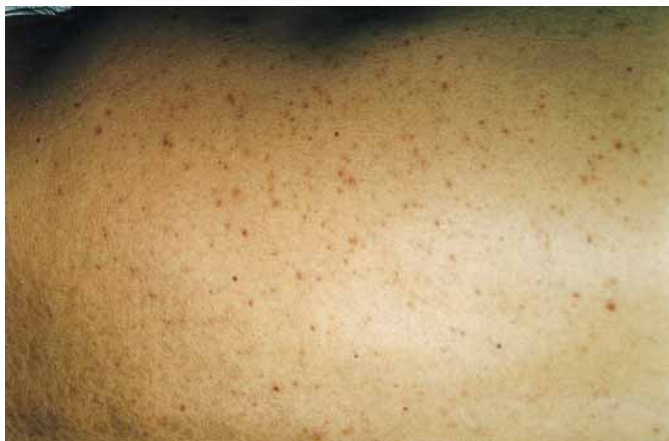

Fig. 1. Maculopapular rash over the trunk of the patient.

fever or leukopenia, or as a potentially lethal pneumonitis. Other clinical manifestations include colitis, ulcerative gastrointestinal ulcers, esophagitis, hepatitis, cholecystitis, pancreatitis, renal failure, meningoencephalitis, and rarely, myocarditis and chorioretinitis (1, 3). However, skin manifestations are extremely infrequent. We present a case of biopsy-proven CMV skin involvement that resolved after appropriate antiviral therapy, and we review the spectrum of dermatologic lesions associated with CMV infection.

Case report

A 56-year-old man with a cadaveric kidney transplant developed fever, diarrhea, and worsening of kidney function 4 months after transplantation. He had a history of hypertension and uric acid kidney stones, and had been on hemodialysis for the last 5 years. Both patient and donor were CMV positive. He received as induction therapy basiliximab 40 mg on days 0 and 4 post-transplant, plus mycophenolate mofetil, methylprednisolone, and cyclosporine. He had received intravenous ganciclovir for the first 14 days post-transplant and then oral ganciclovir for 3 months as prophylaxis for CMV disease.

On admission the patient was dehydrated, hypotensive, and febrile; he was on methylprednisone 10 mg/day, mycophenolate mofetil 3 g/day, cyclosporine 200 mg/day, and diltiazem 300 mg/day. Cyclosporine trough levels varied between 250 and 300 ng/dl, and intravenous fluids were administered. A kidney biopsy was consistent with acute tubular necrosis. Due to long-standing and serious diarrhea, a colonoscopy was performed and disclosed numerous colonic ulcers, which were randomly biopsied but were non-diagnostic (CMV early antigen and immune-staining were negative). Myco-

phenolate was reduced to 2 g/day, the cyclosporine dose was diminished to 100 mg/day, and diltiazem was discontinued. Blood, urine, and stool cultures and toxin tests for *Clostridium difficile* were repeatedly negative. Tuberculosis and fungal serologic tests and serum chemistries were non-contributory. An abdominal ultrasound and computed tomography scan of the thorax were within normal limits. Viremia and antigen pp65 tests for CMV (performed four times during hospitalization) were also negative. Fundoscopic examination was unremarkable, except for grade one hypertensive retinopathy.

Three days after hydration, his renal function improved. The patient remained febrile (39°C on average), anorectic, and with copious amounts of mucous and bloody stools. Mycophenolate was reduced to 1 g/day. Ten days after admission he developed a maculopapular rash that was predominantly distributed over the trunk

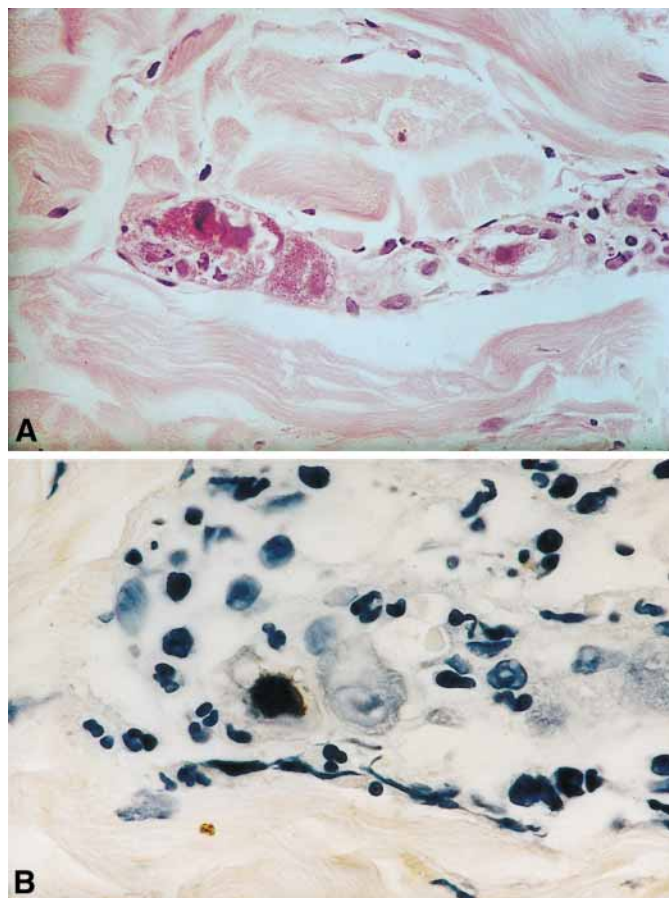


Fig. 2. A: Endothelial large cell with basophilic cytoplasm and large oval basophilic intranuclear inclusions; HE (×500). B: Two stromal dermic cells: one of them is immunostained with monoclonal antibodies against CMV (brown, nuclear staining); the other is markedly enlarged with an intranuclear inclusion body and granular cytoplasmic inclusions (×40).

(Fig. 1). A skin biopsy was consistent with CMV infection, disclosing cytomegalic cells with large intranuclear inclusions surrounded by a clear halo in dermal endothelial cells (Fig. 2A), later confirmed by immunohistochemistry (Fig. 2B). He was started on a 14-day course of intravenous ganciclovir.

By the eighth day of antiviral therapy the skin lesions resolved, and 3 days later his diarrhea disappeared. His basic immunosuppression regimen was reinstated; he became afebrile one day before discontinuation of ganciclovir and was subsequently discharged. Four months after discharge, the patient is asymptomatic with normal renal function.

Discussion

According to the current literature, cutaneous diseases of renal transplant recipients may be classified as follows: lesions of functional/aesthetic interest; skin infections (bacterial, fungal, viral); genital tract diseases (human papillomavirus infection, neoplasm); and precancerous and neoplastic lesions (5).

CMV is a member of the herpesvirus family, widely distributed in humans. After initial infection, it persists in a latent asymptomatic state. CMV clinical syndromes (neonatal and congenital disease, infectious mononucleosis-like illness, transfusion-associated disease) occur infrequently in the immunocompetent host. CMV infection and/or disease are commonly diagnosed in the immunocompromised patient. In this setting, involvement of the skin by CMV is rarely diagnosed and presents as nonspecific lesions, often associated with fever and multisystemic viral disease. The vast majority of patients with CMV skin involvement develop fever, are severely compromised, and usually die (1, 6).

Several presentations of CMV skin lesions may be seen: 1) nonspecific eruptions, as a generalized maculopapular rash, which can also be rubelliform, scarlatiniform, macular, or papular, and can be triggered by previous administration of ampicillin; urticarial eruptions; indurated hyperpigmented nodules or plaques; vesicobullous lesions and sheet-like desquamation; 2) a localized ulcerative lesion, typically genital, perianal, or perineal, although necrotic lesions of the tongue, buccal mucosa, and pharynx have also been reported (5–7).

Involvement of vascular endothelium appears in all presentations; indeed, with the more diffuse eruption, viral lesions may be circumscribed to the vascular endothelium, while the local ulcerative

lesions appear to be associated with more widespread disease. Besides the characteristic cytomegalic cells with intranuclear and intracytoplasmic inclusions, cytologic changes (cytomegaly, irregular shape, nuclear hyperchromatism, and smudging) and prominent neutrophilic infiltration in the CMV-infected blood vessel walls are noteworthy (5–8).

It has been postulated that the dermis is a relatively inhospitable site for CMV replication such that skin involvement occurs only in those patients severely compromised or immunosuppressed. Renal transplant recipients have reduced systemic and cutaneous immunologic surveillance. This is due to the impaired function of circulating T helper cells and to the decrease both in number and in the antigen-presenting capability of Langerhans cells (9). In the compromised host, CMV is activated from its latent state. A viremia ensues, accompanied by fever. A generalized exanthematous eruption may occur in which CMV infects endothelial cells of cutaneous capillaries. This eruption may clear or may evolve into either a cutaneous maculopapular eruption or a cutaneous vasculitis with petechiae or purpura. If severe vascular damage exists, cutaneous infarction occurs, resulting in lesions (possibly nodules) that ulcerate (6).

In our patient, the maculopapular rash appeared 10 days after the onset of persistent fever, superimposed on steroid- and cyclosporine-induced acne. It was non-pruriginous, non-confluent, and distributed over the trunk, predominantly in the neck area. The time of onset, the characteristics of the rash, and the clinical picture led to the suspicion that the maculopapular eruption was CMV-related. The skin biopsy proved to be a rapid, safe, and efficient method to obtain a prompt diagnosis and therefore hastened appropriate treatment.

Regarding the colonic ulcers, we believe they were CMV-related despite the fact that immunohistochemistry studies failed to confirm our clinical impression, as the diarrhea resolved after ganciclovir administration. Acute tubular necrosis was attributed to dehydration, and cyclosporine could have played an additional role.

The immunosuppressed patient with fever and rash can present a challenging clinical problem. Physicians caring for transplant patients must be aware of the possibility of disseminated CMV disease when fever is accompanied by a generalized, nonspecific rash or skin ulcerations. The rarity of CMV skin involvement may be due to underdiagnosis, as nonspecific skin lesions are frequently overlooked. Skin biopsy may document the disease before cultural or serologic confirmation is available, and an early diagnosis and specific treatment may consequently reduce the mortality of this potentially fatal infection.

References

1. RUBIN R. Infectious diseases complications of renal transplantation. *Kidney Int* 1993; 44: 221–236.
2. RUBIN R, TOLKOFF-RUBIN N, OLIVER D, et al. Multicenter seroepidemiologic study of the impact of cytomegalovirus infection on renal transplantation. *Transplantation* 1985; 40: 243–249.
3. HIBBERD P, SNYDMAN D. Cytomegalovirus infection in organ transplant recipients. *Infect Dis Clin North Am* 1995; 9: 863–877.
4. MARKER S, HOWARD R, SIMMONS R. Cytomegalovirus infection: A quantitative prospective study of three hundred twenty consecutive renal transplants. *Surgery* 1981; 89: 660–671.
5. BARBA A, TESSARI G, BOSCHIERO L, CHIEREGATO G. Renal transplantation and skin diseases: review of the literature and results of a 5-year follow-up of 285 patients. *Nephron* 1996; 73: 131–136.
6. PARISER R. Histologically specific skin lesions in disseminated cytomegalovirus infection. *J Am Acad Dermatol* 1983; 9: 937–946.
7. PATEL R, PAYA C. Cytomegalovirus infection and disease in solid organ transplant recipients. In: BOWDEN RA, LJUNGMAN P, PAYA C, eds. *Transplant Infections*. Philadelphia–New York: Lippincott-Raven Publishers, 1998: 229–244.
8. LESHER J, AUGUSTA G. Cytomegalovirus infections and the skin. *J Am Acad Dermatol* 1988; 18: 1333–1338.
9. SERVITJE O, SERON D, FERRE I, CARRERA M, PAGEROLS X, PERY J. Quantitative and morphometric analysis of Langerhans cells in non-exposed skin in renal transplant patients. *J Cutan Pathol* 1991; 18: 106–111.